

# Paget's Disease of Maxilla with Paranasal Sinuses: A Case Report

AMURTHAM VEERAMANI<sup>1</sup>, RR MAHENDRA RAJ<sup>2</sup>, SARAVANAN THALAIMALAI<sup>3</sup>,  
ABIRAMI MOORTHY<sup>4</sup>, PREETHI PARAMASIVAM<sup>5</sup>

(CC) BY-NC-ND

## ABSTRACT

Paget's disease of bone is a chronic skeletal disorder affecting predominantly elderly individuals. The pelvic girdle is the most common site to be affected; however, other sites such as long bones, spine, and skull are also frequently affected. The diagnosis of Paget's disease is made through careful radiographic, biochemical and histopathological analysis. Although involvement of the maxilla is common, the involvement of the paranasal sinuses is comparatively rare. Radiographic presentation of skull lesions ranges from osteolysis to cortical thickening, with characteristic cotton-wool radiopacities and diploe thickening. A rise in serum alkaline phosphatase without a significant elevation in serum calcium and vitamin D levels is regarded as a typical biochemical sign of the disease. Paget's disease of bone often presents asymptotically in most cases until deformity becomes apparent. It is successfully treated with bisphosphonates, a group of anti-resorptive drugs, thereby reducing the associated morbidity and mortality. In the present case, Paget's disease of the skull involving the maxilla with obliteration of the paranasal sinuses was diagnosed in an elderly female who presented with swelling in the posterior maxillary region and markedly elevated serum alkaline phosphatase and parathyroid hormone levels, while calcium and phosphate levels are typically within normal limits. Hereby, the authors present a case report of 64-year-old female patient with Paget's disease of bone with craniofacial involvement resulting in cotton-wool radiopacities of the skull and elevated serum alkaline phosphatase. The patient was under pharmacological management with bisphosphonates and calcium supplements.

**Keywords:** Bisphosphonates, Cotton-wool radiopacity, Fibro-osseous lesion, Hypercementosis, Osteitis deformans, Serum alkaline phosphatase

## CASE REPORT

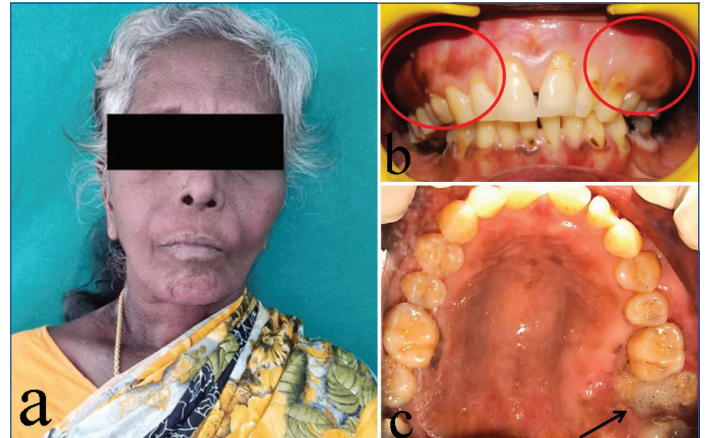A 64-year-old female patient presented to the Oral Medicine Outpatient Department (OPD) with a complaint of swelling in the left upper back teeth region for six months. The swelling had an insidious onset and has slowly progressed to its current size. There was no reported history of pain associated with the swelling. Additionally, the patient mentioned undergoing extraction of a root stump in the left upper back tooth region three weeks before visiting the OPD. There was no significant past medical or surgical history.

On extraoral examination, gross facial asymmetry was noted, with diffuse swelling along the left middle third of the face, measuring roughly 3×3 cm. The swelling extended from the level of the ala tragus line to the level of the angle of the mouth. There were no surface changes noted, and the swelling was hard and non tender.

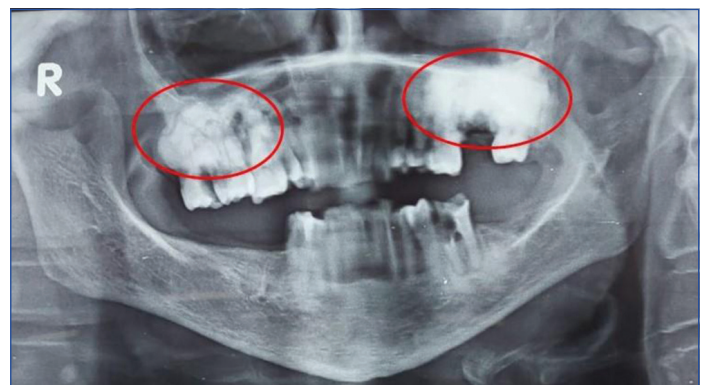Intraoral examination revealed a well-defined bony hard swelling in both the right and left posterior maxilla, with relation to teeth 15, 16, 17, 18 and 25, 26, 27, 28. The swelling extended superior-inferiorly from the mucogingival junction to the level of the marginal gingiva, and mediolaterally from the midpalatal region to the slope of the alveolus along teeth 15 to 18 and 25 to 28. The alveolar mucosa overlying the swelling was normal, with no surface changes observed. An unhealed extraction socket was noted in the 27 region. The swelling was non tender, with no evidence of any discharge [Table/Fig-1a-c].

Based on the clinical examination and the patient's history, the provisional diagnosis is given as a fibro-osseous lesion of the maxilla. The differential diagnosis includes Paget's disease, odontogenic cysts, fibrous dysplasia, and calcifying epithelial odontogenic tumour.

The patient was advised to undergo biochemical and radiographic examinations. Biochemical analysis was performed, revealing elevated serum alkaline phosphatase and parathyroid hormone. An orthopantomogram, along with lateral and posteroanterior skull views, was taken. The orthopantomogram showed a well-defined,

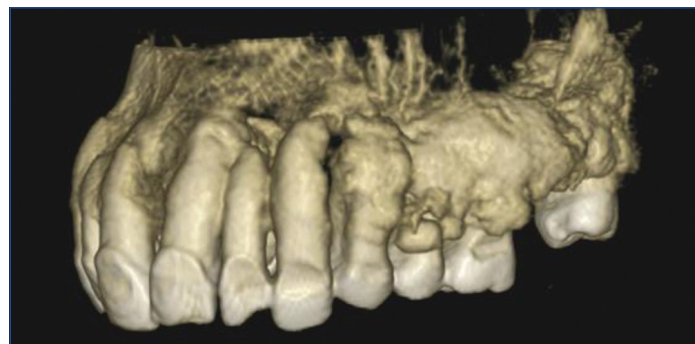

[Table/Fig-1]: a) Extraoral picture demonstrating the facial asymmetry along the left middle third of the face; b) Intraoral images demonstrating the swelling in the right and left posterior maxillary region; c) Unhealed extraction socket in upper left second molar.

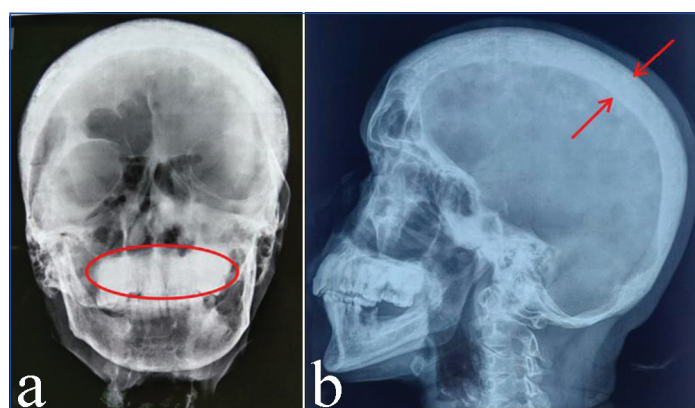


[Table/Fig-2]: Orthopantomogram demonstrating the focal radiopacities with cotton-wool appearance in maxillary right and left molar regions.

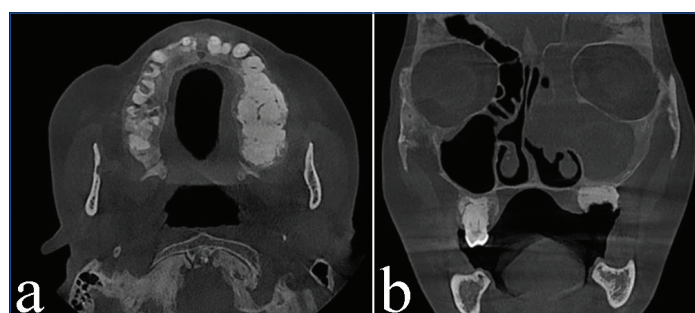
bilateral focal radiopacity with a cotton-wool appearance in the maxillary right and left molar regions [Table/Fig-2]. Hypercementosis was evident in the right and left posterior maxillary teeth [Table/Fig-3]. The skull views demonstrated widening of the diploe space [Table/Fig-4a,b]. Further, cross-sectional imaging using Cone Beam Computed Tomography (CBCT) was recommended. The CBCT study confirmed the presence of cotton-wool radiopacity in the right and left posterior maxilla. Opacification was noted in the left maxillary and ethmoidal sinuses with involvement of the left nasal cavity. The frontal sinuses were completely opacified, and the sphenoidal sinuses were partially opacified [Table/Fig-5a,b]. An Anteroposterior (AP) view of the pelvis was taken to rule out involvement of the pelvic girdle [Table/Fig-6]. Although the initial considerations for differential diagnosis included fibrous dysplasia, calcifying epithelial odontogenic tumour, and odontogenic cysts, a bone biopsy was recommended. However, the patient was not willing to undergo any invasive procedures at the moment. The clinical, biochemical, and radiographic presentation led to the final diagnosis of Paget's disease of the skull involving the maxilla and resulting in the obliteration of the paranasal sinuses. The patient is currently undergoing pharmacological intervention with a weekly regimen of tablet alendronate 70 mg and daily calcium supplements for three months, with active follow-up. After three months of follow-up, biochemical investigations showed a marked reduction in serum alkaline phosphatase [Table/Fig-7].



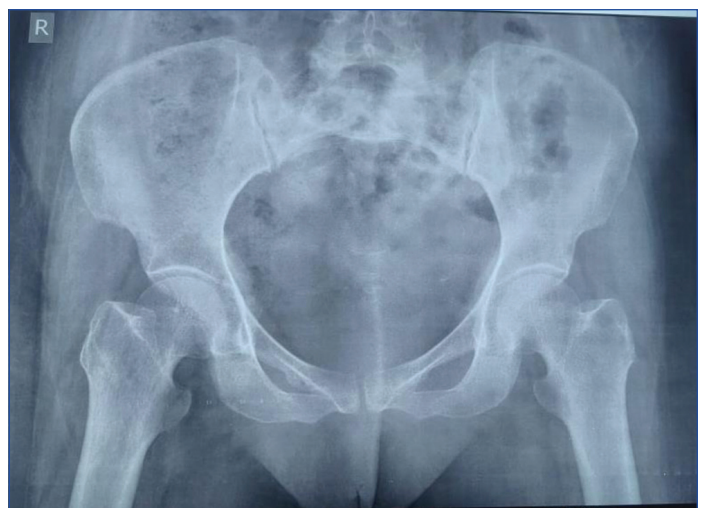[Table/Fig-3]: 3D view of CBCT maxilla showing hypercementosis (bulbous roots).



[Table/Fig-4]: a) Posteroanterior skull view; b) Lateral skull view demonstrating the widening of the diploe space of the skull.



[Table/Fig-5]: a) Axial CBCT slice demonstrating the cotton-wool radiopacity in the right and left posterior maxillary alveolus; b) Coronal CBCT slice demonstrating the involvement of the paranasal sinuses.



[Table/Fig-6]: X-ray anteroposterior view of the pelvis shows no involvement of the pelvic girdle.

Parameters	Observed values	Review after 3 months	Normal values
Serum alkaline phosphatase	936 U/L	491 U/L	38-126 U/L
Serum calcium	8.2 mg/dL	8.0 mg/dL	8.4-10.2 mg/dL
Serum phosphorous	4.0 mg/dL	4.1 mg/dL	3.4-4.5 mg/dL
Serum parathyroid hormone	116.7 pg/mL	107.4 pg/mL	10-65 pg/mL
Serum vitamin D	8.6 ng/mL	11.6 ng/dL	20-50 ng/mL
Serum urea	20 mg/dL	20 mg/dL	20-40 mg/dL
Serum creatinine	0.5 mg/dL	0.5 mg/dL	0.7-1.2 mg/dL

[Table/Fig-7]: Results of biochemical analysis of serum of the patient.

## DISCUSSION

The craniofacial complex is a unique structure that tends to be affected by a wide range of skeletal disorders, including Paget's disease, also called Osteitis deformans. Sir James Paget in 1877 was the first to describe this benign deforming, non-inflammatory, non-infectious condition of bone [1]. Paget's disease is characterised by focal remodeling of the bone with abnormally elevated osteoclastic activity and chaotic osteoblastic activity resulting in imbalanced bone resorption followed by deposition of poorly mineralised fibrous bone. Both monostotic and polyostotic forms of the disease have been reported in the literature. However, the pelvis was reported to be the most frequently affected site in more than 70% of cases, followed by the femur, lumbar spine, skull, and tibia [2]. Among the craniofacial skeleton, the maxilla has a greater predilection to be affected than the mandible. Paget's disease of bone was considered a rare disease in the Indian Subcontinent, with the majority of published cases reported among the Western population [3]. The present report describes a case of Paget's disease of the skull involving the maxilla with obliteration of the paranasal sinuses.

Paget's disease of bone is a chronic focal skeletal disorder attributed to a complex, multifactorial etiology. Several genetic, environmental, and viral components have been related to the osteoclastic abnormalities of Paget's disease. An autosomal dominant pattern of inheritance with mutations in the Ubiquitin-associated (UBA) domain of Sequestosome 1 (SQSTM1/p62) and Valosin-containing Protein (VCP) gene have been identified. Additionally, a relationship between paramyxoviral infection and gene mutations has also been reported in the literature [4].

The observations by Gennari L et al., highlighted the familial occurrence of Paget's disease with a prevalence of 9% among first-degree relatives [5]. However, in present case, there was neither a positive familial history nor a previous history of Paramyxovirus infection. The global prevalence of the disease ranges between 1.5% to 8.3% with a slight male predilection [6]. Literature evidence states that Paget's disease is more prevalent above the age of

fifty. However, there are a few reports of the disease occurring in individuals under the age of 40 years [7]. Asirvatham AR et al., reported the mean age of diagnosis of Paget's disease in the South Indian population to be 67±8 years [3]. Similarly, present patient was diagnosed in her sixth decade of life. While the pelvic girdle is the most common site of involvement in Paget's disease of bone, involvement of the skull is reported as the fifth based on the order of frequency of the disease. The maxilla is known to be affected more than the mandible, with a reported prevalence of 17% [8].

In 1940, Childrey JH reported a series of three cases of Paget's disease of the skull with obliteration of the sinuses, where the obliteration of the paranasal sinuses was noted in all three cases [9]. Similarly, in present patient, opacification was evident in the left maxillary and ethmoidal sinuses noted with involvement of the left nasal cavity. The frontal sinuses were completely opacified, and the sphenoidal sinuses were partially opacified. In the present case, the bilateral maxillary alveolus was affected with involvement of the paranasal sinuses. Paget's disease involving the paranasal sinuses is considered less common [10]. The diagnosis of Paget's disease is based on careful radiographic, biochemical, and histopathological examinations. The radiographic presentation of Paget's disease of the skull varies from osteolytic lesions to subperiosteal cortical thickening. Obliteration of the trabecular pattern with a hazy ground-glass appearance may be evident. In the mixed phase of the disease, abnormal bone deposition with fluffy or globular areas characteristically termed as the cotton-wool appearance may be evident. With the advancement of osteolysis of the skull, large radiolucencies of the frontal and occipital bones known as "osteoporosis circumscripta" may be evident. In the late inactive stage of the disease, the skull may demonstrate a prominently enlarged diploic space, referred to as a Tam-o'-Shanter skull [10].

Serum alkaline phosphatase is a widely utilised marker of bone turnover, depicting the activity of Paget's disease. Osteocalcin and procollagen type 1 N-terminal propeptide are markers that depict bone formation [11]. A rise in serum alkaline phosphatase without a significant elevation in serum calcium and vitamin D levels is the typical presentation of the disease, as observed in present case.

In most cases, Paget's disease is asymptomatic and does not require management unless the disease involvement is extensive, symptomatic, and with complications. Bisphosphonate therapy with alendronate, pamidronate, and risedronate is the most commonly used management modality. Surgery may be necessary

for fractures, deformity correction, spinal stenosis with neurological consequences, and joint replacements due to arthrosis [6]. Skeletal complications of Paget's disease include pathologic fracture, osteoarthritis, hearing loss, and malignancies such as osteosarcoma [12]. In the present case, although a bone biopsy was advised, the patient was not willing to undergo any invasive procedures at the moment. The patient is currently undergoing pharmacological intervention with a weekly regimen of alendronate, a daily calcium supplement for three months, and is under active follow-up.

## CONCLUSION(S)

Paget's disease of bone is often asymptomatic, as in present case, but the deformities associated with disease progression and advancing age may affect the quality of life in affected individuals and predispose them to untoward complications. Therefore, early recognition of the disease, along with appropriate intervention and long-term follow-up, is essential.

## REFERENCES

- [1] Chaudhary M, Prabhakar I, Seth N, Kushwaha S, Sehrawat P. Paget's disease of maxilla: A case report. *International Healthcare Research Journal*. 2017;1(4):15-19.
- [2] Ralston SH. Clinical practice. Paget's disease of bone. *N Engl J Med*. 2013;368(7):644-50.
- [3] Asirvatham AR, Kannan S, Mahadevan S, Balachandran K, Sampathkumar G, Sadacharan D, et al. Is paget disease of bone more common in south India? Clinical characteristics, therapeutic outcome and follow-up of 66 patients from Tamil Nadu. *Indian J Endocrinol Metab*. 2020;24(4):306-11.
- [4] Reddy SV. Etiologic factors in Paget's disease of bone. *Cell Mol Life Sci*. 2006;63(4):391-98.
- [5] Gennari L, Rendina D, Falchetti A, Merlotti D. Paget's disease of bone. *Calcif Tissue Int*. 2019;104(5):483-500.
- [6] Banaganapalli B, Fallatah I, Alsubhi F, Shetty PJ, Awan Z, Elango R, et al. Paget's disease: A review of the epidemiology, etiology, genetics, and treatment. *Front Genet*. 2023;14:1131182.
- [7] Maatallah K, Ben Nessib D, Labbène E, Ferjani H, Bouaziz M, Kaffel D, et al. Paget's disease of bone in patients under 40 years: Two case reports and review of the literature. *Sultan Qaboos Univ Med J*. 2021;21(1):e127-31.
- [8] Bender IB. Paget's disease. *J Endod*. 2003;29(11):720-23.
- [9] Childrey JH. Paget's disease of the bones of the skull with obliteration of the sinuses. *Arch Otolaryngol*. 1940;31(2):333-38. Doi: 10.1001/archotol.1940.00660010335009.
- [10] Theodorou DJ, Theodorou SJ, Kakitsubata Y. Imaging of Paget disease of bone and its musculoskeletal complications: Review. *AJR Am J Roentgenol*. 2011;196(6 Suppl):S64-75.
- [11] Shankar S, Hosking DJ. Biochemical assessment of Paget's disease of bone. *J Bone Miner Res*. 2006;21(Suppl 2):P22-27.
- [12] Shaker JL. Paget's disease of bone: A review of epidemiology, pathophysiology and management. *Ther Adv Musculoskelet Dis*. 2009;1(2):107-25.

### PARTICULARS OF CONTRIBUTORS:

1. Postgraduate Student, Department of Oral Medicine and Radiology, Karpaga Vinayaga Institute of Dental Sciences, Chengalpattu, Tamil Nadu, India.
2. Head, Department of Oral Medicine and Radiology, Karpaga Vinayaga Institute of Dental Sciences, Chengalpattu, Tamil Nadu, India.
3. Professor, Department of Oral Medicine and Radiology, Karpaga Vinayaga Institute of Dental Sciences, Chengalpattu, Tamil Nadu, India.
4. Postgraduate Student, Department of Oral Medicine and Radiology, Karpaga Vinayaga Institute of Dental Sciences, Chengalpattu, Tamil Nadu, India.
5. Postgraduate Student, Department of Oral Medicine and Radiology, Karpaga Vinayaga Institute of Dental Sciences, Chengalpattu, Tamil Nadu, India.

### NAME, ADDRESS, E-MAIL ID OF THE CORRESPONDING AUTHOR:

Dr. Amurtham Veeramani,  
Postgraduate Student, Department of Oral Medicine and Radiology, Karpaga Vinayaga Institute of Dental Sciences, GST Road, Chinnakolambakkam, Palayanoor Post, Madurantakam Taluk, Chengalpattu District-603308, Tamil Nadu, India.  
E-mail: amurthamveeramani@gmail.com

### PLAGIARISM CHECKING METHODS: [Jain H et al.]

- Plagiarism X-checker: Apr 16, 2024
- Manual Googling: May 27, 2024
- iThenticate Software: Jun 04, 2024 (14%)

### ETYMOLOGY: Author Origin

EMENDATIONS: 6

### AUTHOR DECLARATION:

- Financial or Other Competing Interests: None
- Was informed consent obtained from the subjects involved in the study? Yes
- For any images presented appropriate consent has been obtained from the subjects. Yes

Date of Submission: **Apr 15, 2024**

Date of Peer Review: **May 24, 2024**

Date of Acceptance: **Jun 05, 2024**

Date of Publishing: **Aug 01, 2024**